



A Sponsored Supplement From

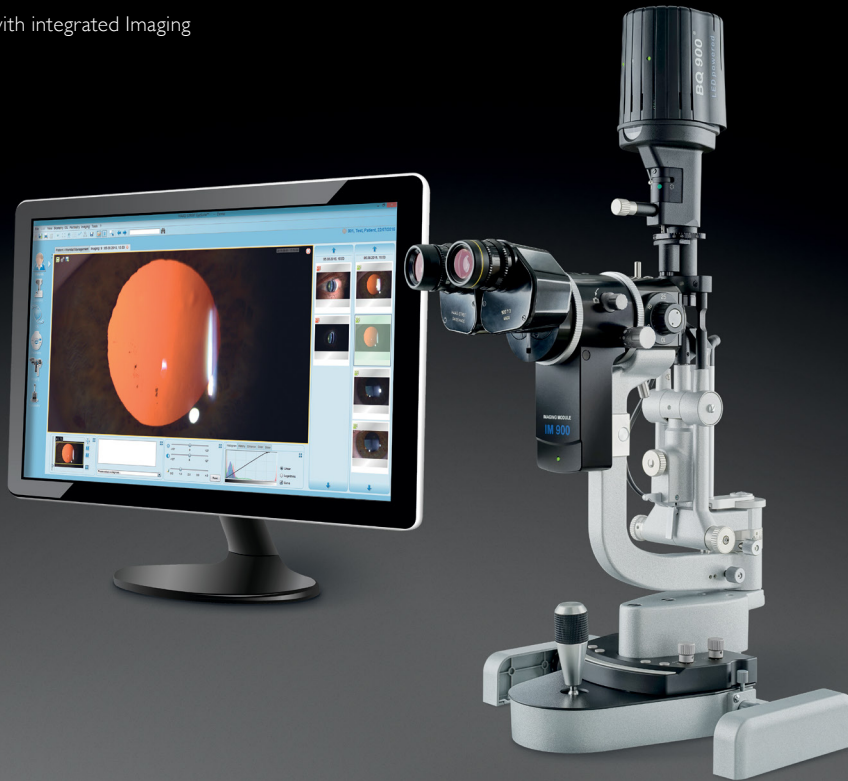the
Ophthalmologist

Worth a Thousand Words

Pearls from the Leaders
in Slit Lamp Imaging



Haag-Streit BQ 900 with integrated Imaging Module 900.

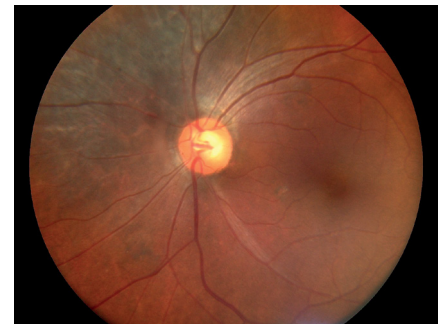


Benefits of Slit Lamp Imaging in Daily Routine

03 Michael E. Snyder, MD, Cincinnati Eye Institute, USA, describes the importance of slit lamps imaging systems in a modern ophthalmic practice.

Imaging in Ocular Surface Disease

09 Jesús Conejero, Hospital de Mérida, Spain, describes how the use of dyes help in identifying and assessing ocular surface disease.



Slit Lamp Imaging – A Guide to Basic Technique

06 Steve Thomson, Sales and Marketing Manager, Haag-Streit Diagnostics, shares his tips for getting the best results from slit lamp imaging systems.

Graphic Details: From Gonioscopy to Goniography

11 Mark Maio, Director Sales and Product Marketing, General Diagnostics, HAAG-STREIT USA, INC., explains how to create the best conditions for using the gonio lens.

Fundus Documentation on the Slit Lamp

13 Michael Korenfeld, MD, President at Comprehensive Eye Care, explains how the Fundus Module 300 helps his busy practice run smoothly.

Benefits of Slit Lamp Imaging in Daily Routine

What place does slit lamp imaging occupy in the modern ophthalmology clinic? We asked Michael E. Snyder, MD (Cincinnati Eye Institute, USA).

How important is slit lamp imaging in your clinical practice?

It's crucial! I see lots of unusual cases, and while verbal descriptions are always useful, the maxim that a picture is worth a thousand words is abundantly true in medicine. Notes in the medical record are often just a brief reminder of the patient's condition, but imaging allows us to capture a moment in time and compare it with the observed condition after weeks, months or even years.

What are the main advantages of slit lamp imaging?

One advantage is that it enables us to precisely track the patient's condition and compare it from one visit to the next. Such tracking may not be so important for conditions such as cataract, but in other cases—for example, in corneal inflammatory disease or ocular surface tumors—subtle changes can occur from one visit to the next. These can be very difficult to express in words, but a picture captures it all and provides a reference point for assessment over time. In some longer-term corneal inflammatory diseases, the original image will be a valuable resource as much as a year later. Slit lamp imaging is an equally excellent means of following the very short-term, day-to-day changes associated with conditions, such as corneal infectious diseases. Photographs really assist clinical judgements regarding improvement or decline in a patient's condition.

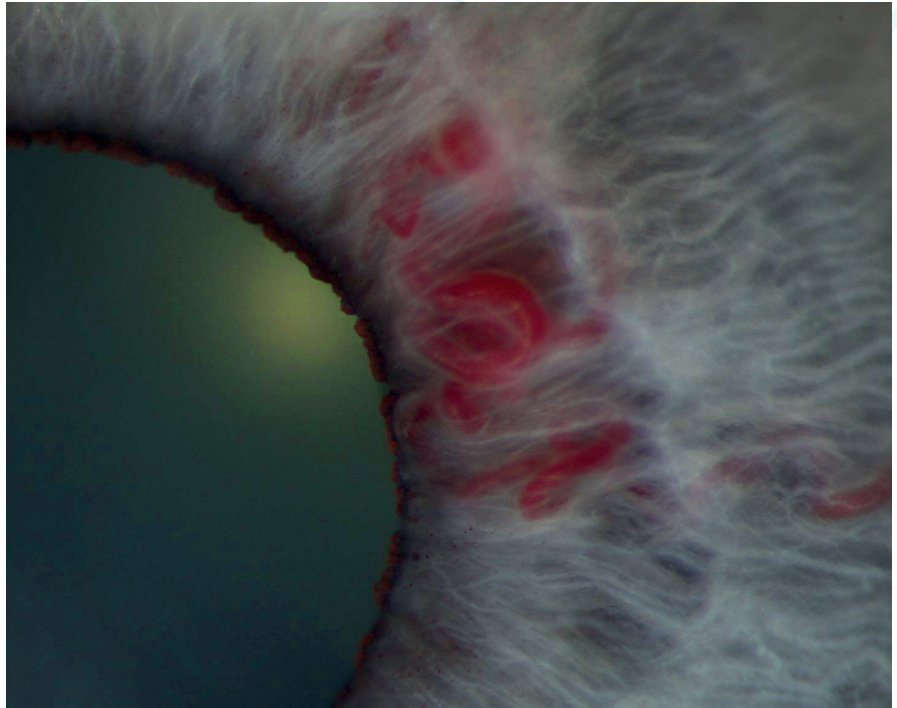


Figure 1. Anomalous iris vessels.

Another area where slit lamp imaging has had a significant impact on our work is the clinical trials field. Some trials require us to track the orientation of an implanted lens at different post-surgery time-points; for this, we rely on slit lamp camera technology. Increasingly, the slit camera is invaluable for guiding the manufacture of custom artificial irises for patients with a natural iris that is deficient in some way. We've found the Haag-Streit slit lamp imaging system ideal for obtaining images of the uninjured or unaffected eye; we then provide these images to the iris device manufacturer, who refers to them when making a custom device to match the normal eye. In this case, the slit lamp image is a direct, essential and integral component of the delivery of patient care.

Fundamentally, slit lamp imaging helps us to take better care of our patients. And it has an impact beyond the practice that uses it; we can capture treatment outcomes in visual form and educate our colleagues via presentations or publications. You could

say slit lamp images enable us to help not just our own patients but also patients in other practices—and that's very gratifying, because we want to make things better for all ophthalmology patients, wherever they may be.

“Notes in the medical record are often just a brief reminder of the patient's condition, but imaging allows us to capture a moment in time.”




Figure 2. Stretched zonules.

What about workflow impact – do you take slit lamp images for all patients?

No, but our patient volumes are high, and not everybody requires slit lamp imaging. That said, we do capture slit lamp images for patients who are undergoing toric implant lens placement, because the instrument allows us to identify useful landmarks, such as penetrating vessels or other anatomical features. With those images, we have a reference point from the upright position whatever the patient's orientation: for example, if they are lying down for surgery and the globe is rotated, we still know where the astigmatism is relative to when the keratometry was measured in the upright position.

In terms of the flow, at the Cincinnati Eye Institute we're very fortunate to have several slit lamp cameras, and I actually have a slit lamp imaging system in the rooms where I work. Therefore, in our situation the workflow depends more on the patient's condition than on the instrumentation. If I'm assessing the effect of topical chemotherapy on an ocular surface tumor, for example, I would examine that patient with the slit lamp imaging system in my room, capture the images myself and then compare them with prior images from visit to visit.

Many of our ophthalmologists prefer to leave all image capture to our awesome ophthalmic photographers, but – being a little compulsive – I prefer to capture pathology-based images myself, in the examination room. Our ophthalmic photographers capture our toric orientation images, outside my workflow.

Tell us about slit lamp image quality.

I'm fortunate to have the Haag-Streit BQ 900 slit lamp; this video capture-based imaging system allows me to capture 30 frames at a time and then select the best-focused image. This feature is particularly useful in patients who find it difficult to keep still or who can't fixate well, such as children. Similarly, in patients with very high amplitude nystagmus, the eye often moves too much for us to effectively examine it. But the slit lamp video imaging capability locks each frame and lets us select which frame to study, making examination of these patients a little easier.

And if we want a very high-quality image; for example, one that we will want to enlarge or publish, we'll opt for the Haag-Streit BX 900 slit lamp in the exam room across the hall. This instrument has a greater degree of lighting control and a much higher resolution than the BQ 900

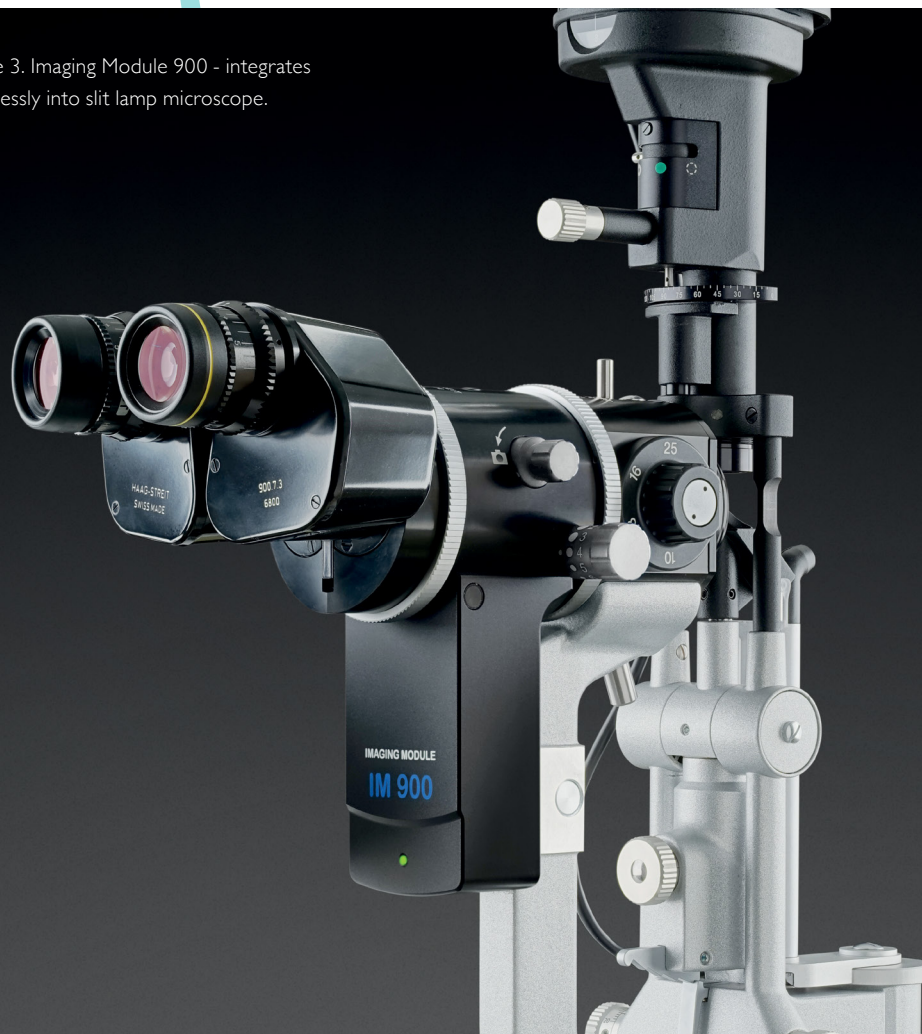model, and thus provides ultra high-resolution, professional quality images. The BQ 900 works extremely well for regular daily practice, but the BX 900 is more detailed by an order of magnitude: it can even capture single cells circulating in the anterior chamber, or single red blood cells passing through tiny capillaries.

In our practice, the two systems are complementary. I mostly use the BQ 900 model, primarily because its video-based system allows me to see the image on my monitor during the exam; that speed of operation is very helpful in a busy clinic. Also, for the overwhelming majority of my patients, the BQ 900 system is extraordinarily good and captures images of resolution that are more than acceptable for almost all uses. The BX 900 system achieves much higher resolution than BQ 900, but at the cost of frame numbers: to capture more detail per frame, it only captures one frame at a time. Also, it can take a little more time to capture the higher resolution images because the system may need fine adjustments of illumination or depth of field. Nevertheless, it's fairly straightforward to use and is my go-to instrument when I need to enlarge an image for presentation or publication. Overall, I am thrilled with the quality of the images that I'm able to capture with my slit lamp instruments!

How do you store the images?

The Haag-Streit EyeSuite Software, which comes with the slit lamp camera, has a robust storage system, which allows images to be annotated with the patient's information; it also allows image adjustment and manipulation – for example, we can crop the image and adjust tone, brightness, color or contrast. Furthermore, images stored within this system can be directly exported into various electronic medical records databases, using autoscripts, without losing the original image from the EyeSuite. In addition, we can directly export images

Figure 3. Imaging Module 900 - integrates seamlessly into slit lamp microscope.



from the slit lamp camera system onto other hard media, such as a USB drive, which can be useful if we need images in a format suitable for academic purposes.

Who should use slit lamp imaging?

Any eye care provider can benefit from these imaging systems. The BQ 900 video imaging capability allows the patient and family to see the examination on the television monitor, which many people find reassuring – they like to see what we can see. And from an educational perspective – it helps everyone if we can show the patients the pertinent features of their

condition; not least, it helps the patients trust their physician! For practices that see many cases with significant pathology, it's extraordinarily useful to capture images and compare them over time. And for those involved with treating iris abnormalities, particularly in the context of implanting artificial iris devices, slit lamp camera systems are a crucial resource.

What about the learning curve?

My first experience with a slit lamp imaging system was similar to my first experience with the earliest Macintosh computer. With no previous Macintosh

experience, I became productive within 15 to 20 minutes of first using it. I found the slit lamp imaging system to be equally intuitive: the software is fairly easy to navigate even if, like me, you don't like reading the instructions beforehand! So new users shouldn't expect any particular problems; indeed, those who are good with IT systems may find that they can manipulate the database system in all kinds of advantageous ways. There may be other ways to capture these images, but it is difficult to compete with the superb resolution offered by the slit lamp camera system.

Slit Lamp Imaging – A Guide to Basic Technique

By Steve Thomson



Figure 1. BQ 900 slit lamp with integrated IM 900 camera.

Slit lamp cameras are becoming more popular and are now regularly provided as part of the clinical instrument. The convenience of having the ability to document patients' eye disease is widely accepted and technology is assisting with this rapid evolution. Camera sensors have improved in recent years. The impact of these developments can be seen in improvements to camera sensitivity, the added ability to image a wide dynamic range of tones and faster data transmission. This now enables clinicians to photograph the anterior eye with minimal impact on their work flow.

This short article seeks to provide some guides on how clinicians can make best use of these tools and how, with some consideration to the image rather than their clinical view, they can

improve the quality of their patient documentation.

The Clinical Examination

In order to make good images there must be an understanding of the difference between the clinical examination and the imaging process. The examination provides the clinician with the complete 'picture' of the patient. The data gathered clinically is observed in three dimensions and the dynamic exam provides feedback on the relative size and scale of the features. When a photograph is made, it is a brief moment from this dynamic exam and is captured in only two dimensions, and therefore much of the clinical information is not recorded. This is the main reason why the stereoscopic view through the slit lamp is a challenge to replicate digitally.

The first consideration for any slit lamp photograph is that the scene should be captured with the audience in mind. It is highly likely that the viewer will not have the benefit of the clinical exam and so only have the image details to assess. This may involve the use of supplementary or background illumination and, in narrow slit imaging, more detail can be revealed by simply increasing the angle between the illumination source and microscope. The selection of the appropriate magnification and composition within the camera frame is also a small consideration that is often overlooked. The following paragraphs discuss some of the slit lamp settings and controls that can be adjusted to help improve image detail and quality in the most common clinical images.

The Overview Image

The overview image is generally one used to set the scene. In routine practice several images using different illumination techniques may be required

to record the eye and the low magnification overview can be useful to provide a reference.

Wide diffuse illumination is achieved by fitting the diffusing filter in front of the slit mirror. The level of illumination should be set to around 50% of output (or less if the patient cannot tolerate this) and the slit beam opened to maximum. A second diffuse illumination can be used to provide balance to the image and help improve the spread of illumination over the whole frame. The background illuminator has uses in other techniques but in the overview image is used to facilitate slide illumination. Setting an angle of 30 – 45 degrees between both illumination sources on either side of the microscope can have a detail enhancing effect.



Figure 2. Diffuse illumination between 30-45 degrees from microscope produces even lighting over the whole field.

The high sensitivity of modern slit lamp cameras can be utilised to improve the depth of field in such images and, with a device where the imaging aperture can be controlled, a magnification of 10x can have a focus range from the corneal apex to conjunctiva and sclera.

The diffuse, shadowless illumination can be used to document gross pathology such as the simple recording of the iris, eyelids and margins, and the highly reflective and irregular

conjunctiva. This technique is generally not suitable for the imaging of fine details in the cornea or the other semi-transparent media of the anterior eye.

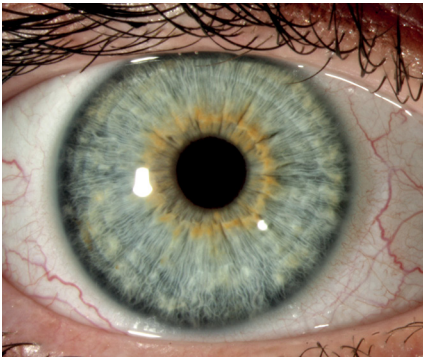


Figure 3. Diffuse Illumination.

Slit Illumination

The slit illumination can be divided into two sections; firstly fine slit (or optical sections) will be discussed followed by moderate slit width imaging.

The cornea and lens are not absolutely transparent and when an intense, finely focused beam of light is introduced at a wide angle to the viewer, details of the structure can be observed within the illuminated beam. In slit lamp biomicroscopy this is often referred to as an optical section.

Creating an optical section image is challenging as the focus is critical, the illumination is relatively low compared to the levels of diffuse illumination, and the required magnification is usually higher in order to make the structures visible. The optical section effect can only be observed with a slit width of less than 0.2 mm and therefore the slit lamp illumination should be set to maximum. A useful guide is that if the patient finds the illumination too bright then it is likely that the slit is too wide. Most patients can tolerate this maximum illumination with a very thin slit.

The observation angle between incident and reflected light must be large in order to compensate for the

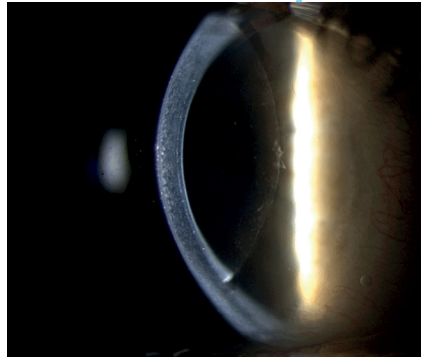


Figure 4. Fine slit illumination showing the structure of the cornea and increased reflection from intracorneal lens.

two-dimensional view. While this may seem unfamiliar to the observer, the image created can provide remarkable detail. When imaging the cornea the goal should be to achieve an angle of 70 – 90 degrees separation. In the lens, due to limitations of pupil size, this angle may have to be reduced. Maximum detail will be seen with no background illumination but in some situations a small amount of diffuse light can be used to help orientate the viewer. Care should be taken to ensure that the corneal reflex from the background illumination does not compromise the slit illumination.

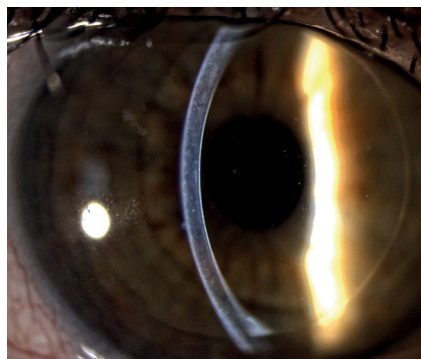


Figure 5. A small amount of background illumination can help orientate the viewer.

The aperture control of the slit lamp is likely to be close to maximum therefore the depth of field is shallow.

A magnification of 16x or 25x should be used however selecting a lower magnification can improve the image quality as the relative aperture is increased. Good camera systems will allow a little post capture cropping that can help compensate for this lower magnification. Light loss and microsaccadic eye movements make fine slit photography at 40x a real challenge, even for the experts.

Moderately wide focal slit illumination can be useful to demonstrate the separation between anterior and posterior cornea and furthermore, can be used much like a spotlight to highlight some pathologies. Imaging using a slit beam of between 1 – 2 mm is relatively easy compared to fine slit imaging as up to 20x more light energy is available to make the image. Generally patients will not be able to tolerate maximum illumination and so it should be reduced to an acceptable level. An image captured with a moderate beam is often complemented by a fine slit optical section image to provide maximum information.




Figure 6. A 1 mm slit is used to show separation in the cornea. Note the endothelial cysts and intracorneal nerve. Further endothelial pathology can be seen in with indirect illumination reflected from the iris.

The illumination angle for a moderate beam is generally narrower than that required for optical sections as the

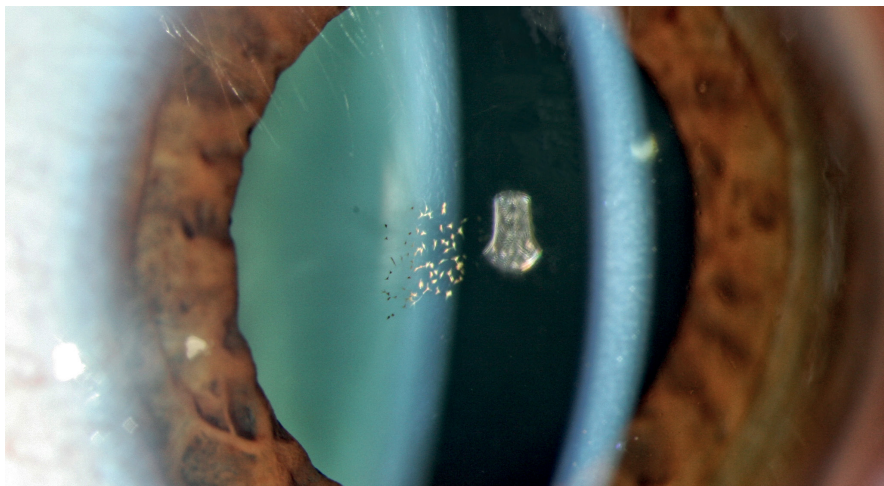


Figure 7. A moderate slit beam focused on the anterior surface of the lens illuminates epicapsular stars.

overlapping surface details can confuse the observer. Typically around 45 degrees is optimal. With significantly more energy the aperture can be reduced to increase the depth of field. Care should be taken to ensure that any corneal reflexes are moved away from the camera axis.

Refining Technique

High quality clinical slit lamp photography can be achieved by non-ophthalmic photographers due to the improvements made in camera technology and image capture systems. The technique is different from the clinical slit lamp examination. However, with small changes to workflow and an understanding of the challenges involved, most images can now be created in the examination room.

The appreciation that imaging uses only one of the ocular paths is fundamental. Flare and unwanted reflections that are normally suppressed by the binocular view can be distracting on the image and a little time should be dedicated to ensure these do not compromise the camera view. The illumination tower is supported by slim columns and when the angle between the microscope and illumination tower is small this should also be monitored.

The eyepiece setting is critical and the

dioptrre setting should be adjusted to compensate for the operator's refraction, accommodation and any myopia that can be introduced by the telescope effect. If the screen image is out of focus but the slit lamp view in focus, it is most likely an effect of an incorrect eyepiece setting and this can easily be adjusted. A further means to minimise this effect is to view the PC screen when making the image. This can ensure that the image is in good focus and is reflex free.

Well-designed image capture software can also complement the imaging process and features such as 'History Trigger' can be used effectively to ensure that the perfect image is captured every time. A history trigger is a circular buffer of images that are continually refreshed in the live mode. Pressing the camera trigger stops this process and gives around 50 images (2 seconds) captured immediately prior to when the image was captured. This can prove useful in optimising the image quality to select the best frame, removing patient blinks, and in children can be the difference to capturing an image or not.

Generally the exposure setting is automatic and these smart systems can correctly decide the exposure setting in the majority of cases without the need for manual adjustment. The manual override

is simple to initiate, but care should be taken to ensure that images are not over exposed. There is a surprising amount of detail present in an image that is slightly darker than ideal but this can be optimised in post-capture processing. Over exposed images cannot be so easily improved and therefore it is best to aim for an image where the bright, highly reflected regions are correctly exposed and then look to improve the darker areas using software.

Summary

Technology has advanced in recent years and the latest devices can remove many of the challenges that are often to be considered in slit lamp photography. In many cases the automatic exposure will give an image close to what is required and therefore the clinician can concentrate on selecting the best method of illumination to reproduce the clinical view.

Diffuse illumination is used to make the overview photograph and contains sufficient energy to allow for a small aperture selection. This will result in a wide depth of field within the image. Fine slit images must use a wide aperture and only a small portion of the eye is illuminated. Using a fine maximum intensity slit of less than 0.2mm can make structures in the cornea and lens visible with the optical section effect. Although the slit lamp is on the maximum power the depth of field is restricted to less than 0.5mm at 16x.

In order to compensate for the image that is created with a monocular view, the angle between the microscope and illumination column should be increased beyond that used clinically. This, combined with a narrow slit, is fundamental to high quality corneal imaging. Make the final adjustments to focus and image composition by viewing the screen. This can minimise unwanted reflections and flare and ensure correct focus is achieved.

Steve Thomson is Ophthalmic Photographer and an employee of Haag-Streit AG, Switzerland.

Imaging in Ocular Surface Disease

In their native state, pathologies of the ocular surface can be difficult to identify, let alone comprehensively assess – and that’s why we use specialized stains. But to get the most from vital dyes, we must also choose the best observation method.

By Jesús Conejero, Hospital de Mérida, Spain

Diagnosis and assessment of ocular surface disease (OSD) requires examination of the ocular surface with a slit lamp. This specialized microscope provides magnified views of tear film, conjunctiva, cornea, iris and parts of the anterior chamber. Even so, surface lesions and tear film discontinuities can be difficult to resolve, as there may be little contrast between normal and abnormal areas. In these circumstances, we apply stains that are differentially absorbed by normal and abnormal regions respectively, thereby revealing pathology and allowing the physician to more exhaustively assess the ocular surface (1). But which dyes should we choose, and what slit lamp settings should we employ?

Which dye to use

Three main dyes are suitable for staining the living tissues of the eye: lissamine green, rose bengal and fluorescein sodium. Unfortunately, both lissamine green and rose bengal are of relatively limited availability – in particular, lissamine green is not always available at the appropriate concentration. Furthermore, rose bengal may be toxic to epithelial cells, and the discomfort associated with its use often demands concomitant use of anesthetic drops.

However, rose bengal and lissamine green do have advantages, including ease of use (neither require color filters for the slit lamp) and, more importantly, their ability to expose conjunctival epithelial lesions, such as those associated with insufficient tear flow and excessive dryness. Conjunctival lesions precede corneal damage in OSD etiology, and therefore constitute an important early signal of disease.

Fluorescein sodium, by contrast, is more broadly available than lissamine green or rose bengal, but requires a cobalt blue exciter filter for stain visualization. Unfortunately, even with a blue filter, fluorescein sodium cannot provide adequate contrast for in the context of the blueish-white background of the sclera. Hence, the dye is usually thought unsuitable for examination of the conjunctiva, and is more often used to reveal corneal epithelial lesions or to measure tear film ‘break-up’ time. In the past, to get a full picture of OSD – that is, exposure of both corneal and conjunctival lesions – physicians and patients have often been forced to accept the expense and inconvenience of using different stains and waiting longer. But now, accumulated data indicate that appropriate filter choice can make fluorescein sodium actually more effective in visualizing early conjunctival lesions than either rose bengal (2) or lissamine green (3) – without detracting from its ability to reveal other pathology.

Blue versus ‘blue and yellow’

In brief, by blocking blue light coming from the examination field – via the addition of a yellow barrier filter – we provide the conditions for contrast-rich visualization of the entire fluorescein-stained ocular surface. The result? Sharp, clear and information-rich images of a range of ocular surface pathology (Figure 1). Published work shows that

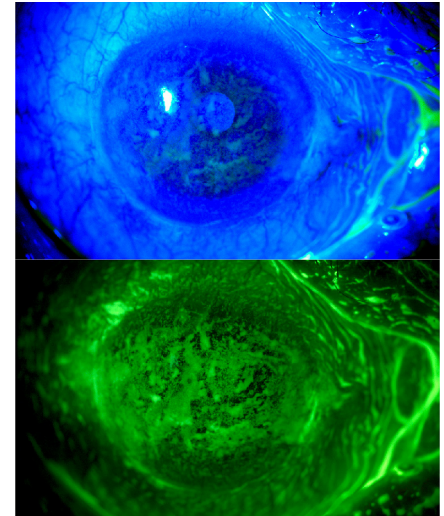


Figure 1. Dry eye syndrome. After fluorescein instillation and cobalt blue light illumination, visualization with a yellow barrier filter provides higher contrast images (Above: fluorescein staining with cobalt blue illumination. Below: after placing in yellow barrier filter).




Figure 2. Yellow filter can be incorporated into the slit lamp microscope.

combining fluorescein sodium with a yellow barrier filter (Figure 2) provides better visualization of conjunctival lesions than either rose bengal or lissamine green in early stages of dry eye syndrome, as well as in detection of damaged corneal epithelium in later stages of OSD (3).

The simple addition of a yellow barrier filter to our slit lamp set-up provides multiple benefits. Firstly, by blocking blue light, we give fluorescein sodium the ability to simultaneously

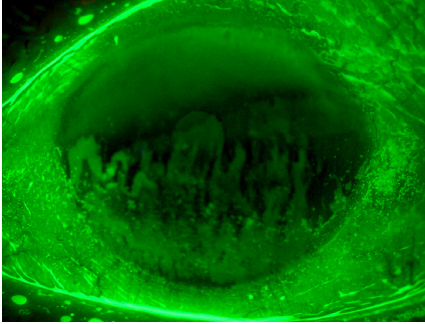


Figure 3. Dry eye syndrome. Corneal and conjunctival epithelial staining. Visualization with cobalt blue exciter filter illumination and yellow barrier filter allows us to examine the corneal and conjunctival involvement using only one vital dye, fluorescein.

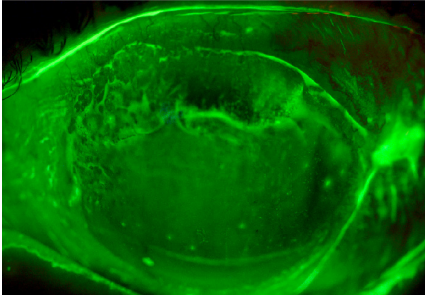
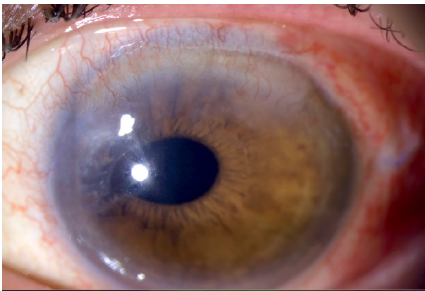


Figure 4. Intraepithelial epithelioma (Bowen's disease). Fluorescein staining and visualization with a yellow barrier filter allows to establish with great accuracy the limits of the lesion over the corneal and conjunctival surfaces.

expose both corneal and conjunctival abnormalities (4), a unique attribute with significant advantages – for both patient and physician – in terms of time and convenience (Figure 3). Secondly, using fluorescein sodium in this way allows us to dispense with rose bengal and lissamine green, and thereby avoid

Slit lamp tips

The basic technique for ocular surface staining by fluorescein sodium is simple. But is that all there is to it? In fact, optimal images of stained tissues may require optimized slit-lamp or camera settings. In particular, the blue light illumination required by fluorescein demands modification of the capture parameters of our camera. Specifically, we must considerably increase the exposure, and often increase the aperture, to maximize light capture when examining the fluorescein-stained eye. Adding a yellow barrier filter will further reduce the light reaching the camera sensor, necessitating further increases to exposure time and aperture dimensions. Users should

be aware that these fine adjustments can delay image capture enough for the fluorescein to pass through epithelial defects into the corneal stroma, resulting in blurred images. Therefore, my recommendation is to ensure that the settings of the slit lamp system, including the camera, are optimized in advance of applying fluorescein to the eye. The general principle is that capture of sharp images requires that we view the tissues reasonably promptly after staining. Finally, wherever possible, use a yellow barrier filter specifically built into and optimized for the slit lamp; simply placing generic yellow filters in front of the slit lamp optic can never, in my opinion, provide images of crispness and contrast equivalent to those obtained when using products optimized for the slit lamp in question.

issues of patient discomfort, ocular surface toxicity and low product availability.

Furthermore, tear film break-up time, film distribution around lesions, positions and limits of conjunctival neoformations, and subtle epithelial changes in certain corneal dystrophies can all be usefully interrogated by the fluorescein-yellow filter technique. For example, it is able to identify anomalous epithelial areas in cases of recurrent corneal erosion and in patients with epithelial basement membrane dystrophy. Similarly, examination of the fluorescein-stained lachrymal film and its distribution around ocular surface structures allows us to very precisely establish the limits of tumoral or pseudotumoral lesions (Figure 4). The technique therefore provides an

excellent adjunct to surgical planning and post-surgery follow-up.

The resulting photographic records support assessment of disease evolution and treatment response, and therefore are of immense clinical value.

References

1. CL Mártonyi, et al., "Slit Lamp. Examination and Photography. Third Edition. Sedona: Time One Ink", 2007.
2. S Koh, et al., "Diagnosing dry eye using a blue-free barrier filter", *Am J Ophthalmol*, 136 513-9 (2003). PMID:12967806
3. Y Eom, et al., "Comparison of conjunctival staining between lissamine green and yellow filtered fluorescein sodium", *Can J Ophthalmol*, 50, 273-277 (2015). PMID:26257220.
4. AJ Bron, "Diagnosis of dry eye", *Surv Ophthalmol*, 45(suppl), S221-S226 (2001). PMID:11587146.

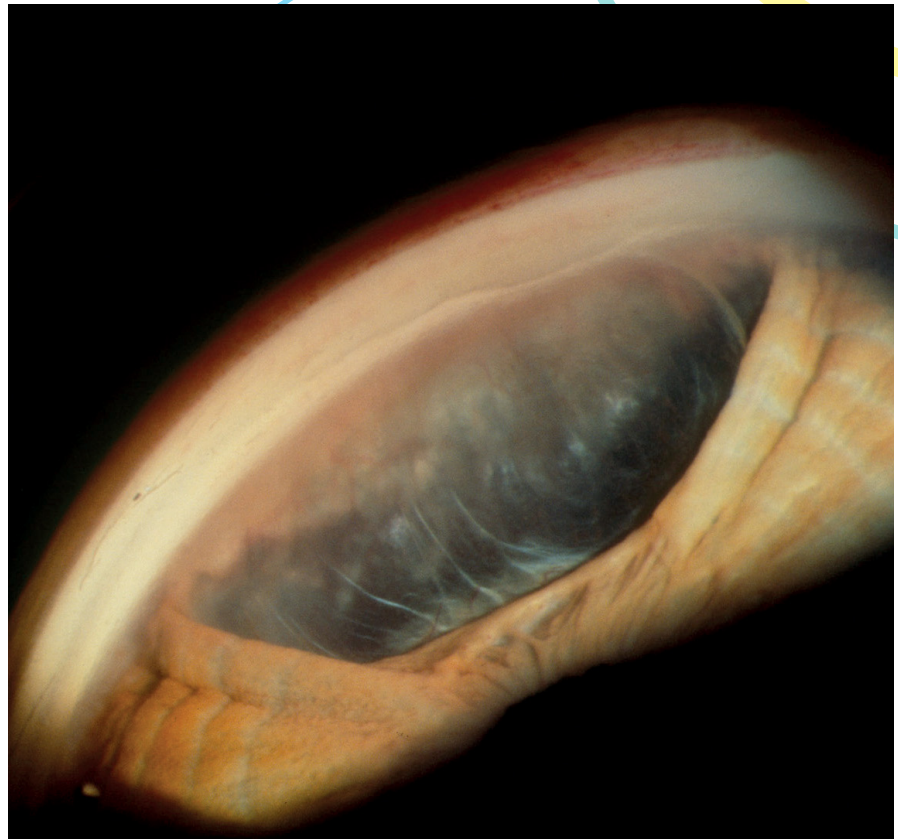
Graphic Details: From Gonioscopy to Goniography

The gonioscopy examination is a dynamic, stereoscopic procedure that uses controlled lighting and magnification to reveal important details of ocular pathology. Recording this information, rather than simply viewing it, requires a shift in mindset; we must capture monocular points in time. But how do we create optimal conditions for still photography through the gonioscope? We asked Mark Maio, Director Sales and Product Marketing, General Diagnostics, HAAG-STREIT USA, INC.

By Mark Maio

What would you say is important about the shift from doing gonioscopy to taking photographs with a gonio lens? The biggest obstacle to getting good gonio photos is that they are done after gonio exams. Obviously, an exam has to be done before the doctor has found some pathology that needs to be recorded photographically. Though the doctor is examining the eye with a gonio lens, the more time they spend on the eye, the more corneal edema they actually induce. This slight increase in edema, though not typically noticed during the exam, causes the image captured to be less sharp and clear than it was when the lens was originally placed on the eye.

If high-quality gonio photographs are what you are trying to achieve, an alternative to consider is scheduling the patient to have photos taken as the first thing you do during their next exam. The majority of pathology we are photographing with the gonio lens does



© Mark Maio

not change that significantly between office visits. As physicians are doing most of this type of photography, it will be hard for them to resist doing their exam instead of concentrating on just making photographs the next time they see the patient. If an imaging-first workflow coincides with the proper care and treatment of the patient during their next exam, you have raised your success rate for better images by 90 percent.

Which cushioning medium do you prefer to use with the gonio lens during imaging? It is quite common to use Goniosol as the cushioning agent when using a gonio lens to examine the cornea. It is a very viscose media that helps make sure that the lens does not scratch the cornea during the exam. The problem using this while making photographs is that, due to its high viscosity, it is also less optically clear. You

do not get as clear an image as if you use something called Genteal. Genteal is less viscose, but it is optically clearer, giving you a sharper view and a better photograph.

Which type of gonio lens do you use for photography?

There is a wide range of different types of gonio lenses used to examine the eye, each used for different purposes. What distinguishes them is the number of mirrors they contain, the size of each mirror and the angle of view each mirror offers. Some gonio lenses have one mirror; others can have up to four. The reason for the multiple mirrors is that once the lens is applied, the lens can be rotated and the eye can be examined from a different angle without the need to apply a different gonio lens.

My standard lens for photography is the Goldmann Three Mirror, which has a small, medium and large mirror.

“Instrumentation can’t do everything for you, so don’t forget to pay attention to your technique.”

The small mirror is typically used for looking at the angle of the eye, almost as if you are inside the eye and you are poking your head up through the pupil looking straight across the iris into the angle.

The middle mirror gives you a perspective as if you are standing on the iris looking down. I typically use this mirror for iris cysts, something on the eye that is elevated.

I use the large mirror in a dilated eye to photograph pathology right behind the iris such as the ciliary process.

You mentioned that increased pressure applied to the eye via the lens results in increased corneal edema – and a photographic image of decreased clarity. What is the ideal method to resist applying pressure to the eye?

Doing a dynamic exam with a gonio lens, the physician holds the lens with the thumb and forefinger of one hand while using the other hand to control the slit lamp. Turning the lens with these two fingers tends to slightly apply pressure to the eye. This pressure, over a short period of time, will cause a small amount of edema in the cornea, which, though not noticed during the exam, reduces the clarity of the image you are trying to capture. By using the thumb and forefinger of each hand together to

gently turn the lens, I have discovered that I am able to reduce the amount of pressure I apply to the eye and get clearer images.

Assuming the patient has returned for their next exam – so you know where the pathology is – I position the mirror I want to use for photography directly across from what I need to photograph to minimize how long I keep the lens on the eye. For example, if I know the pathology is at the three-o’clock position, I would apply the lens to the eye with the mirror I am going to use at the nine-o’clock position – directly across from it. You immediately have the mirror where it needs to be, rather than turning it and pushing on the eye to get it in the correct position. I try to get everything I need for good photographs set on the slit lamp and imaging system before I apply the lens. The less time you spend with the lens on the eye, the sharper your images will be.

What role does patient management play in getting good gonio photos?

I typically spend more time explaining to the patient what I’m going to do than actually photographing. I find that if I get the patient physically comfortable at the slit lamp and at the same time get them to understand what I am going to be doing and how it will feel, it equates to better photographs.

I also make sure that, when I have the patient’s head comfortably in the headrest, the slit lamp is set for a complete range of movements up and down; if you don’t pay attention to the fact that you might be at the top of the range of joystick elevation, you could get the lens on the eye, and as you try to raise the slit lamp into a mirror placed at twelve o’clock, you might run out of upward movement. Making sure that the slit lamp is adjusted correctly is also a quick fix for better images.

Are there any special lighting techniques used with a gonio lens?

Yes, given that most of what we are looking at with the lens is in the angle of the eye. This curved structure of the eye, where the edge of the cornea meets the iris, is best photographed by making the light the same shape as the area that you are putting it in.

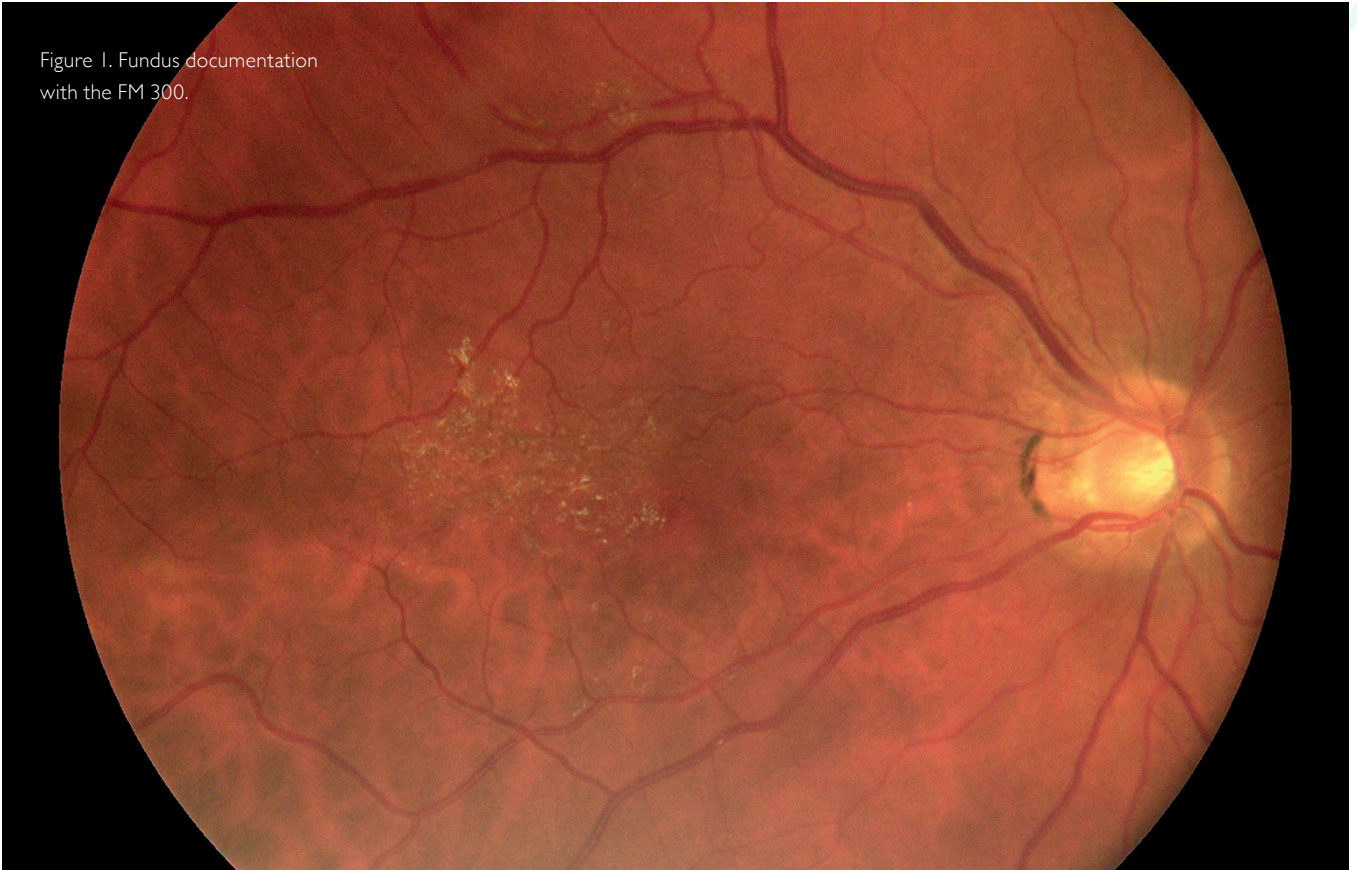I create a half-moon shaped light that mimics the area that I am going to photograph. To make this half-moon light, I choose the 8 mm slit beam height, open the slit beam all the way up to a full circle of light and then slowly turn the height adjustment towards the left or right. Half-way between one setting and the other, the circle will change to a half-moon shape. I make this shape before I put the lens on the eye and it is adjusted and positioned so it goes right into where I am going to place the mirror on the eye.

The hardest part of getting good quality images with a gonio lens is the fact that you are doing your lighting and focusing through a mirror, not directly on the pathology itself. Having all these parameters set up before applying the lens to the eye makes the process easier and quicker. I have found that the faster I can get on and off the eye while making images, the better they are going to be.

Finally, are there any special precautions you take regarding the lens you use?

I have one lens set aside for use only while doing photography and I take extra care cleaning it. This might not be practical for many physicians as they have lenses (or sets of lenses) they use for exams on a routine basis. The problem is each time they are cleaned after an exam, enough attention isn’t given to gently wiping off the flat, front surface of the lens. This continual cleaning causes small scratches on the lens surface which, over time, will compromise photographic image quality. While you will not notice these scratches during the exam, they will cause reflection artifacts during photography.

Figure 1. Fundus documentation with the FM 300.



Fundus Documentation on the Slit Lamp

What impact does the Fundus Module 300 system have on a busy, crowded practice? To find out, we spoke to Michael Korenfeld, MD (President at Comprehensive Eye Care, Ltd, Washington, MO, USA).

How do you use the FM 300 in your daily practice?

In terms of the mechanics of its use, we keep the FM 300 attached to our slit lamp. We can take it off whenever we

want, but there's no need – the camera works cooperatively with the slit lamp, so we can still use the slit lamp as if there were no camera attached. In other words, we just swing out the camera and swing in the slit lamp optics, or vice versa, according to what mode we want. So once the FM 300 is attached to the slit

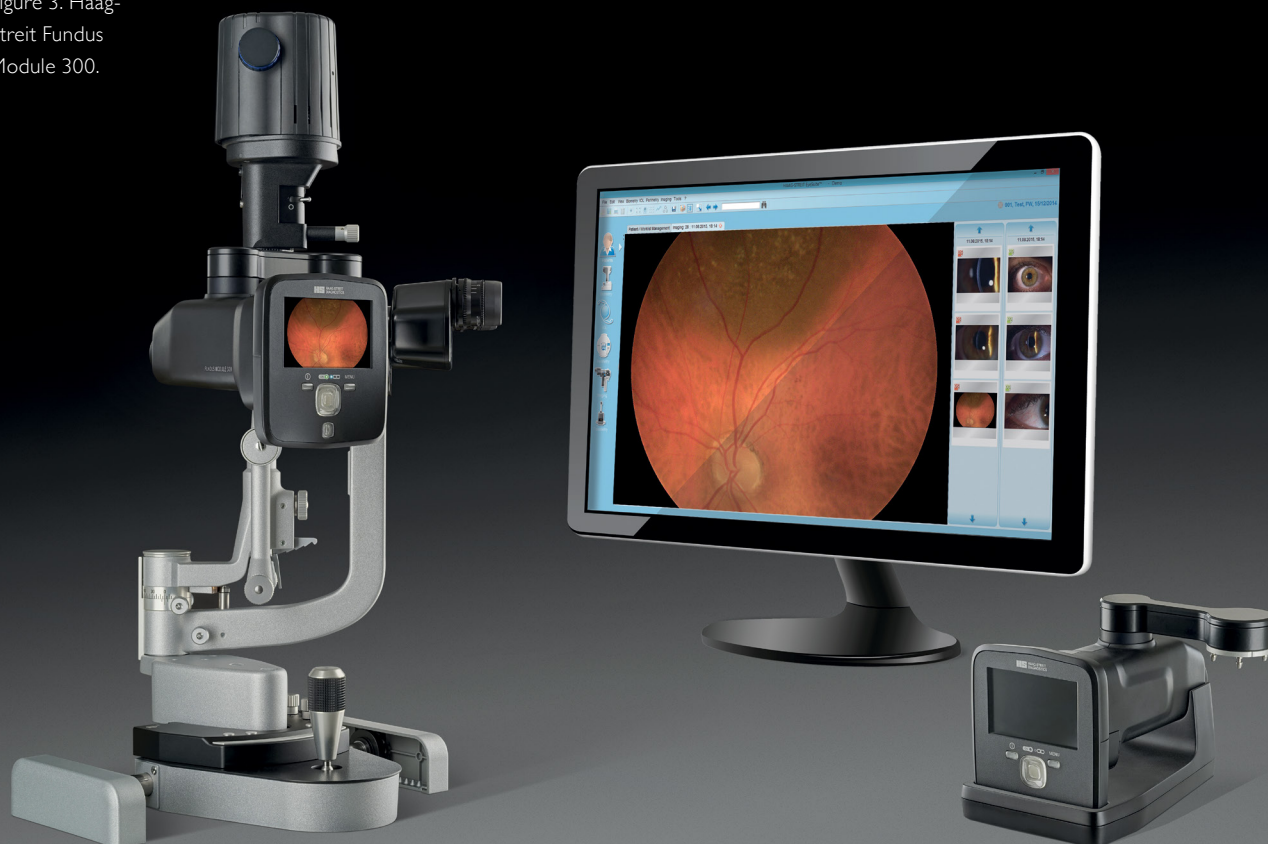

Figure 2. The FM 300 can remain on the slit lamp.

lamp, it's easiest to just leave it there.

In terms of its clinical use, we employ it to quickly and conveniently collect images of the retina and optic nerve head during ocular examinations. Previously, collecting fundus images was difficult and inconvenient – we'd have to go to a separate room and ask a technician to take the picture. But with the FM 300, getting a picture is so easy and quick that there's no need for a technician; furthermore, we can keep the instrument in a room next to our offices. The whole process is fast, efficient and seamless; the time it takes from getting the patient to the instrument to capturing the picture is usually less than three minutes – which is remarkable! And once the image has been captured, we can transfer it from the camera to a computer datafile and

Figure 3: Haag-Streit Fundus Module 300.



simultaneously send it to a monitor screen, which makes for easier assessment, and also allows us to immediately discuss the examination result with the patient and the people who came with them to the appointment.

Also, the FM 300 comes with some very useful and elegant image processing tools – for example, you can change contrast, brightness or size, move it around or enlarge it, and compare the left and right eyes on the same screen. Such features really enhance presentation and discussion of clinical images and information. Hence, in our practice, we routinely use the system not only to demonstrate abnormal findings, but also to illustrate the normal situation.

In particular, it helps us to inform patients about their condition: we can show them a normal eye next to their problematic eye, so they can see the differences for themselves, and we can point out the precise details of their pathology, which can be very helpful. For example, I recently showed one of my patients an FM 300 picture of a tiny particle in one of his retinal capillaries – a potential stroke precursor; his whole approach to his condition changed as he looked at the picture and understood what it meant. There's no doubt that such interactions have a different impact compared with just a verbal explanation – it helps patients take ownership of their conditions and act

accordingly. After all, many conditions that become manifest in the fundus are linked to lifestyle factors that the patient can change. For all those reasons, we think the FM 300 is a very powerful fundus visualization system. Not every FM 300 picture is perfect, but many are – and as the film is free, we can take as many pictures as necessary to get what we need.

And the learning curve?

I first learned about the FM 300 at a trade show last year, and I thought it sounded like a pretty good idea. So, not long after that, I got Haag-Streit to install one of the instruments in my office for me to evaluate. My experience was that

there are non-obvious aspects of the FM 300 system, so users do require a degree of training and experience to become comfortable with all elements. For example, it took us a little while to figure out how to get all parts of the system charged up at the same time – computer, camera, docking station – because you don't just flip a switch to charge everything at once. We also had to learn how to manipulate the camera to change fixation, and how to use the post-processing image software. I would say that there is a learning curve for the new user, but it's not an unusually onerous or lengthy learning process, and once you're familiar with the device, you get a reliable stream of clinically relevant images to help your patients and your practice. That said, we haven't had the FM 300 very long, and it's clear that it has many functions and features, so I envisage that it could take us a year to become fully proficient with all its subtleties to gain further benefits. Nevertheless, a new user can reach the point where they are able to collect and manipulate good pictures in around two weeks.

Does the system have any limitations?

A small limitation is that the camera can't be installed on any Haag-Streit slit lamp – not all models have enough room to position the camera within the slit lamp optics. That said, many of the slit lamp models that are suitable for the FM 300 have been in broad use for several years, so compatibility shouldn't be a major issue for most users.

What impact does FM 300 have on standard workflow and practice?

It has a small footprint, which is very welcome. By using the FM 300 instead of a standard fundus camera, we free up half a room – highly valuable in a crowded office! In turn, it actually improves our workflow by giving us more space to take care of people. At

the same time, it doesn't disrupt our usual ways of doing things at all. For example, our workplace layout hasn't changed, and because it remains familiar to both doctor and patient, everybody still knows what to do. Our patients just jump in the chair, put their chin in the appropriate place and everything proceeds quickly and efficiently.

“By using the FM 300 instead of a standard fundus camera, we free up half a room – highly valuable in a crowded office!”

The FM 300 also contributes to the practice in an economic sense. Every time we take a picture of an eye condition that is reimbursable and supported by medical necessity and appropriate ICD-10 codes, we get paid for taking the picture and storing it. At present, between the two doctors in our practice, we take five to seven pictures per day. So, at an average reimbursement of about \$50 per picture, we probably bill \$300 per day; in 30 days that's \$9,000, which is close to the cost of the device. Therefore, as well as helping patients, the camera helps pay for itself. I'd say we paid for the entire system within three months, which is a very good rate of return on investment for any kind of capital equipment.

In brief, the FM 300 is a very smooth, high-quality system that gives us excellent images in about three minutes, without disrupting the way our clinic works. Unless you need fluorescein angiography – and most people only want still images – the FM 300 can easily replace the standard fundus camera. And, of course, patients always like to see their physician using cutting-edge technology!

What about image quality from the FM 300?

The FM 300 optics are designed for fundus photography in eyes with undilated pupils; in my experience, it is very reliable for that purpose, as long as the patient doesn't have a corneal scar or advanced cataracts. Any opacity in the visual system will reduce picture quality in eyes with undilated pupils – but most of our patients need dilated pupils anyway, so image quality is never an issue for us. In fact, we find that a good proportion of pictures are crisp and clear enough for publication, but even those that aren't perfect give us the information we need for our clinical purposes. We've never had a case where we couldn't get a serviceable image. And remember, once you've captured the image, you can modify it with the software: adjustments to brightness and contrast can turn a disappointing picture into an excellent one.

Final thoughts?

It's worth reiterating that we can use the FM 300, and the images it gives us, in multiple ways. We can use it to support documentation and records, to help us bill for our services, to educate patients about their conditions, and to discuss the surgical plan. We often use the system differently for each patient according to their needs, but all of the options are available for all patients. So, the FM 300 gives you a lot of arrows in your quiver – whatever you need to do, the camera supports it.

